

Submitted:
23.08.2017
Accepted:
01.12.2017
Published:
29.12.2017

Fetal ultrasound: Early diagnosis and natural evolution of proximal femoral focal deficiency

Eugenio O. Gerscovich, Simran Sekhon, Thomas W. Loehfelm, Adam Greenspan

Department of Radiology, UC Davis Health, Sacramento, California, USA

Correspondence: Prof. Eugenio O. Gerscovich, MD, Department of Radiology, University of California, Davis Medical Center, 4860 Y Street, Suite 3100, Sacramento, CA 95817, tel.: (916) 734 0371, fax: (916) 734 6548, e-mail: eogerscovich@ucdavis.edu

DOI: 10.15557/JouU.2017.0043

Keywords

fetus,
ultrasound,
skeletal dysplasia,
proximal focal
femoral deficiency

Abstract

Proximal femoral focal deficiency is an extremely rare congenital anomaly with only a few case reports in the literature. This case illustrates one diagnosed by prenatal ultrasound. The diagnosis may be isolated or associated with other abnormalities and syndromes. This report describes the early obstetrical ultrasound diagnosis, its evolution and associated findings throughout pregnancy. To the best of our knowledge, it is the first report associating this diagnosis with sickle cell trait. Another finding in our patient was a concomitant intrauterine growth restriction that we attribute to placental infarctions and a retro placental hemorrhage, also on the basis of sickle cell trait. At birth, placental weight was under the 10th percentile for gestational age. Obstetrical ultrasound in the prenatal diagnosis of proximal femoral focal deficiency is important, because early recognition of this malformation could provide useful information to parents and physicians regarding newborn management and therapeutic planning.

Introduction

Proximal femoral focal deficiency is an extremely rare congenital anomaly with an incidence of 0.11 to 0.2 per 10,000 births, and with only a few case reports in the literature. It results in shortening of a lower extremity. Risk factors for this pathology are unknown, but it may be isolated or associated with other abnormalities and syndromes.

We describe a patient with an early obstetrical ultrasound diagnosis, its evolution and associated findings.

Case report

A 20-year-old female patient was seen at our institution with an early pregnancy. She was gravida 1, para 0. Physical examination revealed a Body Mass Index (BMI) of 25.09 kg/m² and elevated arterial blood pres-

sure. Clinical history indicated sickle cell trait. Laboratory findings were notable for normochromic, normocytic anemia and mild thrombocytosis. Full maternal screening indicated a low risk. At a clinical estimated menstrual age (EMA) of 22 weeks 1 day, an amniocentesis was successfully performed with normal chromosomal and microarray results.

The progression of relevant sonographic findings is described in Tab. 1, and illustrated in Fig. 1 and Fig. 2.

At a clinical EMA of 37 weeks 1 day, patient underwent induction of labor with a successful vaginal delivery under epidural anesthesia. A female newborn showed Apgar scores of 8 and 9 at 1 and 5 minutes. Fetal weight was 4 lbs. 1 oz (1865 g).

Pathology report of the placenta indicated a small mature placenta with a weight of 227 g (<10th percentile

EMA	Bone lengths			Other findings
	Right femur (%)	Left femur (%)	Other bones (%)	
19 weeks 2 days	1.55 cm (<3 rd)	2.94 cm (21 st)	Normal	Normal bone mineralization
21 weeks	1.44 cm (1 st)	3.3 cm (20 th)	Normal	IUGR (<10 th)
26 weeks 6 days	2.36 cm (<1 st)	4.72 cm (10 th)	(1 st)	IUGR (4 th)
28 weeks 6 days	2.4 cm (<1 st)	5.2 cm (8 th)	(<5 th)	IUGR (6 th)
31 weeks	3 cm (<3 rd)	5.5 cm (10 th)	(<5 th)	IUGR (<3 rd)
33 weeks	3 cm (<3 rd)	5.5 cm (3 rd)	(3 rd)	IUGR (<3 rd)
35 weeks	3.3 cm (<3 rd)	6.1 cm (<3 rd)	(<3 rd)	IUGR (<3 rd)

EMA – estimated menstrual age; (%) – percentile

Tab. 1. Chronological progression of ultrasound findings

for gestational age) and chorioamnionitis stage 1 (mild). Pathology examination showed a retroplacental hemorrhage measuring 3.5×1.8 cm without parenchymal compression. Adjacent to this area there were 2 central infarctions measuring $2 \times 1.8 \times 1.2$ cm and $1.8 \times 1.5 \times 1.2$ cm, respectively. They occupied about 10% of the small placenta. There were no intervillous thrombi. The distal end of the umbilical cord showed a focal hemorrhage extending into the surface of the placenta. Bacteriology studies were negative. Of the serology studies, the only positive one was for varicella-zoster. The sonographic appearance of the placenta was unremarkable throughout the pregnancy.

The newborn was admitted to the Newborn Intensive Care Nursery. Physical examination showed a marked shortening of the right lower extremity (Fig. 3), with a normal range of motion, no hip dislocation and normal reflexes. There was symmetrical length of both calves. She was discharged home 2 weeks after delivery, with a weight of 2004 g.

Genetic consultation at an age of 3 months observed a prominent forehead, midfacial hypoplasia with flat nasal bridge, hypertelorism, telecanthus and micrognathia.

Orthopedic consultation at 2.5 months of age agreed with the ultrasound diagnosis, and reported a right hip flexion contracture of 40 degrees and a knee flexion contracture of 30 degrees (Fig. 3). A single radiograph of the lower extremities obtained at the same age (Fig. 4) showed a short right femur, approximately half the length of the left one, with pseudoarthrosis of the right femoral neck and superolateral subluxation of the hip with mild anterior flexion. The ossification center for the distal right femoral epiphysis was normal.

Discussion

Proximal femoral focal deficiency (PFFD) is a rare congenital anomaly characterized by dysgenesis and hypoplasia of variable segments of the proximal femur, with

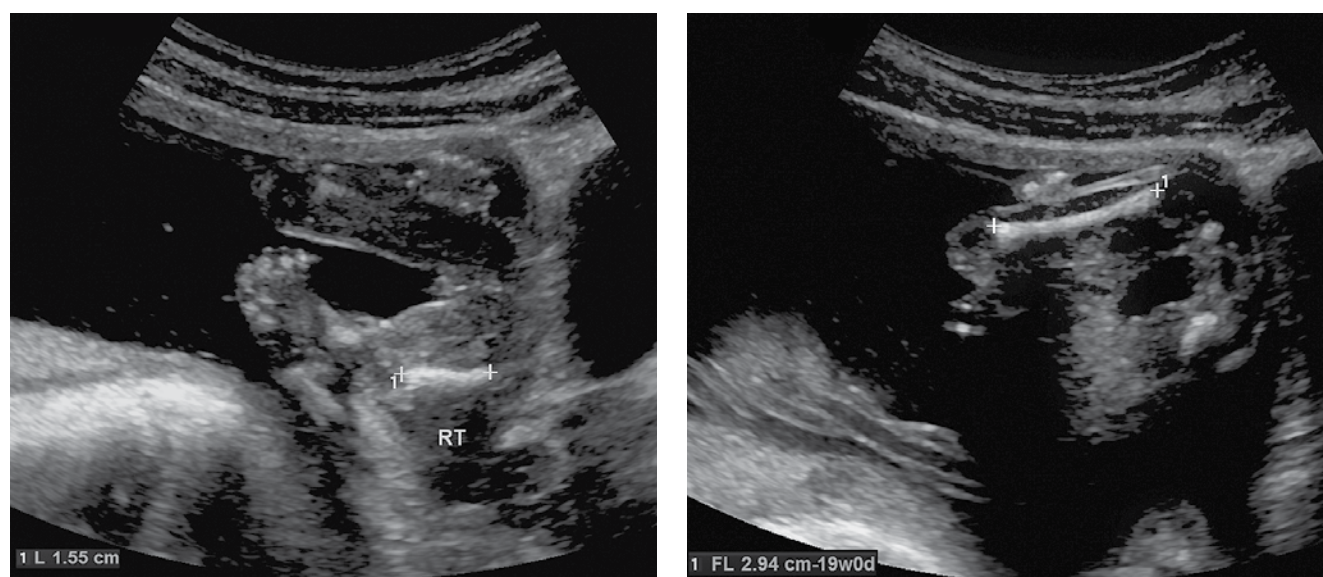


Fig. 1. Proximal femoral focal deficiency, prenatal ultrasound. Clinical EMA of 19 weeks. Short right femur of 1.55 cm. Normal left femur of 2.94 cm. (calipers = femur, RT – right, FL – femur length)

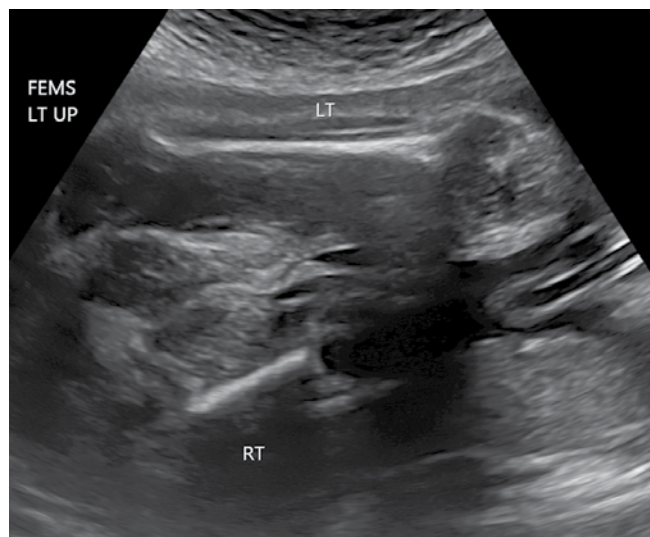


Fig. 2. Proximal femoral focal deficiency, prenatal ultrasound. Clinical EMA of 28 weeks 6 weeks. Both femurs. Right femur measures in the <1st percentile. Left femur measures in the 8th percentile. (LT – left, RT – right)

an incidence of 0.11 to 0.2 per 10,000 births⁽¹⁾. Several etiologic factors have been implicated, including diabetes mellitus, exposure to thalidomide, viral infections, exposure to radiation, chemical toxicity, and trauma to the fetus between the 4th and 8th weeks of gestation^(2,3). The defect ranges in severity from femoral shortening associated with varus deformity to complete absence of both the acetabulum and proximal femur. The condition may be bilateral (rare) or unilateral (85–90% of cases), and may be associated with other congenital abnormalities, however, it is not associated with any chromosomal abnormalities. Associated abnormalities reported in the literature include: oligodactyly of the hand⁽⁴⁾, fibular agenesis or hemimelia, absence of cruciate ligaments or patella, spinal deformities, and club foot deformity^(5,6).

Several classifications of PFFD have been proposed. The most practical one from the prognostic point of view is the classification system offered by Levinson and colleagues: Type A: the acetabulum is normal, the femoral head is present, and the femoral segment is short. There is varus deformity of the femoral neck. Type B: the femoral head is present but there is absence of osseous connection between the head and the short femoral segment. The acetabulum exhibits dysplastic changes. Type C: The femoral head is absent or presented by an ossicle. The femoral segment is short and tapered proximally. The acetabulum is severely dysplastic. Type D: the femoral head and acetabulum are absent. The femoral segment is rudimental, and the obturator foramen is enlarged⁽⁷⁾.

As stressed in the literature, prenatal diagnosis of PFFD is important, because early recognition of this malformation could provide useful information to parents and physicians regarding management and therapeutic planning^(4,5). Prenatal ultrasound is widely used to

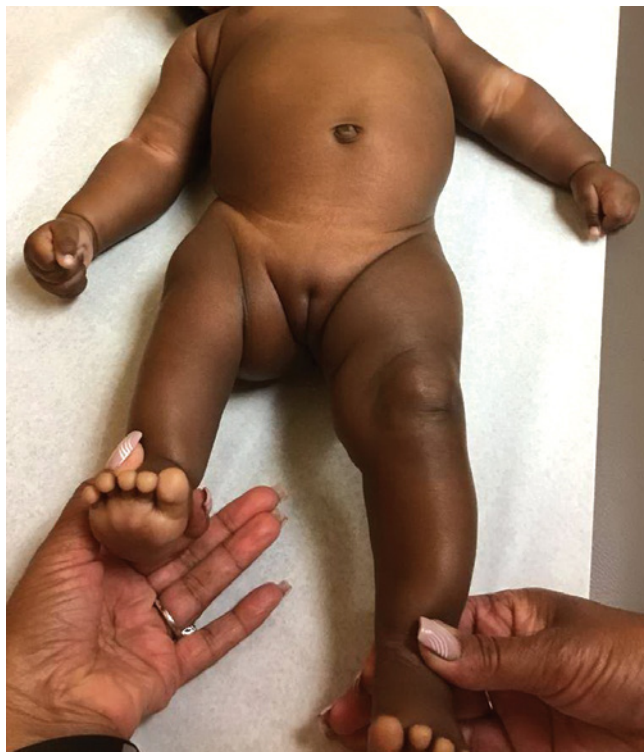

Fig. 3. Proximal femoral focal deficiency. Photograph of the infant at 3 months of age. Short right lower extremity

screen for all sort of fetal anomalies, including PFFD. The most common method to diagnose the latter abnormality, if it is unilateral, is a difference in the biometry of the two femora⁽⁸⁾. The ratio of femoral length discrepancy in reported cases varied between 0.64 and 0.85^(9,10). The measurements should be obtained according to the guidance of the International Society of Ultrasound in Obstetrics and Gynecology and the American Institute of Ultrasound in Medicine^(11,12). When PFFD diagnosis is suspected on ultrasound examination, other congenital anomalies should be excluded, such as femoral–facial syndrome, femur–fibula–ulna syndrome⁽¹³⁾, and more severe deformities like thanatophoric dysplasia, achondrogenesis, achondroplasia, chondroectodermal dysplasia.

Based on the anatomic and biometric sonographic findings at an EMA of 19 weeks 2 days, a presumptive diagnosis of proximal focal femoral deficiency was made. From then on, the patient was reexamined every few weeks. Our interpretation of these findings and their progression is that the fetus initially presented with an isolated unilateral PFFD, and then rapidly developed early intrauterine growth restriction (IUGR), that we attribute as being responsible for the diffuse shortening of all other long bones. We think that the IUGR was unrelated to the PFFD. All bones maintained normal mineralization and shape, excluding thus most osteochondral dysplasias. The lack of absence of other bones excluded the possibility of femur–fibula–ulna syndrome. There were no oligodactyly of the hands, clubbed feet or spi-

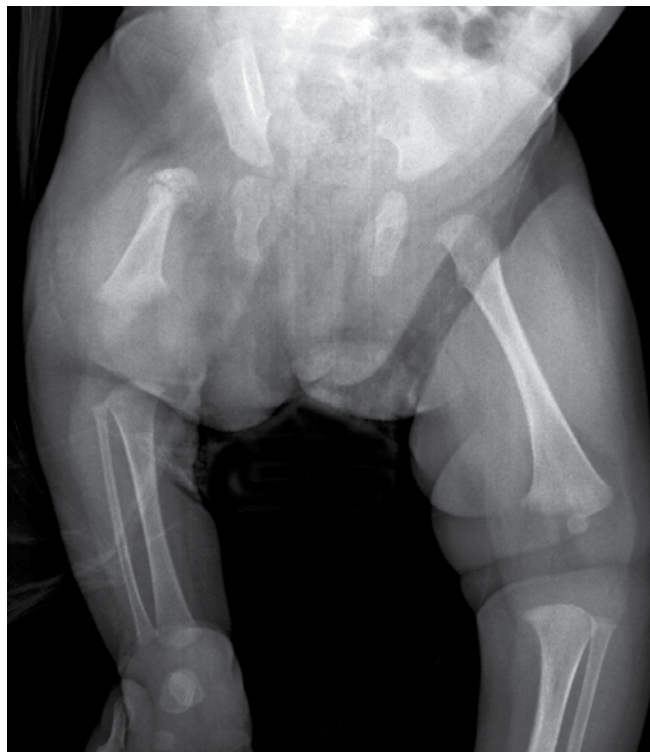

Fig. 4. Proximal femoral focal deficiency. Radiograph of the lower extremities at the infant's age of 2.5 months demonstrates a short right femur associated with pseudoarthrosis of the femoral neck, superolateral subluxation of the hip and symmetrical length of tibiae and fibulae

nal abnormalities, as reported in other cases. Regarding the possibility of femoral–facial syndrome in which facial abnormalities are observed, we could not recognize any on ultrasound, but the genetic consultation at an age of 3 months observed a prominent forehead, mid-facial hypoplasia with flat nasal bridge, hypertelorism, bilateral telecanthus and micrognathia. It is likely that

References

- Hillmann JS, Mesgarzadeh M, Revesz G, Bonakdarpour A, Clancy M, Betz RR: Proximal femoral focal deficiency: Radiologic analysis of 49 cases. *Radiology* 1987; 165: 769–773.
- Gonçalves LF, De Luca GR, Vitorello DA, Parente LM, Philippi H, Saab Neto JA *et al.*: Prenatal diagnosis of bilateral proximal femoral hypoplasia. *Ultrasound Obstet Gynecol* 1996; 8: 127–130.
- Bronstein M, Deutsch M: Early diagnosis of proximal femoral deficiency. *Gynecol Obstet Invest* 1992; 34: 246–248.
- Otera Y, Morokuma S, Yumoto Y, Hojo S, Gotoh T, Hara T *et al.*: Prenatal three-dimensional images of proximal focal femoral deficiency produced by helical computed tomography. *Fetal Diagn Ther* 2009; 25: 349–353.
- D'Ambrosio V, Pasquali G, Squarcella A, Marcoccia E, De Filippis A, Gatto S *et al.*: Prenatal diagnosis of proximal focal femoral deficiency: Literature review of prenatal sonographic findings. *J Clin Ultrasound* 2016; 44: 252–259.
- Kudla MJ, Beczkowska-Kielek A, Kutta K, Partyka-Lasota J: Proximal femoral focal deficiency of the fetus – early 3D/4D prenatal ultrasound diagnosis. *Med Ultrason* 2016; 18: 397–399.
- Levinson ED, Ozonoff MB, Royen PM: Proximal femoral focal deficiency (PFFD). *Radiology* 1977; 125: 197–203.
- Mailath-Pokorny M, Timor-Tritsch IE, Monteagudo A, Mittal K, Konno F, Santos R: Prenatal diagnosis of unilateral proximal femoral focal deficiency at 19 weeks' gestation: Case report and review of the literature. *Ultrasound Obstet Gynecol* 2011; 38: 594–597.
- Lin TH, Chung CH, Shih JC, Lin CH, Lee CN, Su YN: Prenatal diagnosis of proximal femoral focal deficiency: A case report and literature review. *Taiwan J Obstet Gynecol* 2013; 52: 267–269.
- Lessoway VA, Schulzer M, Wittmann BK: Sonographic measurement of the fetal femur: Factors affecting accuracy. *J Clin Ultrasound* 1990; 18: 471–476.
- American Institute of Ultrasound in Medicine: AIUM practice guidelines for the performance of obstetric ultrasound examinations. *J Ultrasound Med* 2010; 29: 157–166.
- Salomon LJ, Alfirevic Z, Berghella V, Bilardo C, Hernandez-Andrade E, Johnsen SL *et al.*: Practice guidelines for performance of the routine mid-trimester fetal ultrasound scan. *Ultrasound Obstet Gynecol* 2011; 37: 116–126.

our patient falls into this syndrome. Filly *et al.* observed a similar situation in one of their patients⁽¹³⁾.

Several etiological factors have been described in PFFD, as above. None of those can be found in our patient. In our patient, we find a history of sickle cell trait with normochromic, normocytic anemia associated with mild thrombocytosis and elevated arterial blood pressure. We postulate that perhaps this ailment may be responsible for the PFFD and the small placenta. In turn, the small placenta with its infarctions and hemorrhage could be responsible for the IUGR. We could not find a previous report indicating an association of PFFD and sickle cell anemia. Ours could be the first one.

Management of PFFD requires a multidisciplinary and individual approach, based on leg-length discrepancy and status of the musculature. Surgical corrections include conversion of the knee to a hip joint by flexing it 90 degrees and fusing the femur to the pelvis, or Van Nes' so-called turn-about-procedure (rotationplasty) to convert the foot into the knee joint, followed by fitting the short limb with a leg prosthesis⁽¹⁴⁾.

Conclusion

Obstetrical ultrasound in the prenatal diagnosis of PFFD is important, because early recognition of this malformation could provide useful information to parents and physicians regarding newborn management and therapeutic planning.

Conflict of interest

Authors do not report any financial or personal connections with other persons or organizations, which might negatively affect the contents of this publication and/or claim authorship rights to this publication.

13. Filly AL, Robnett-Filly B, Filly RA: Syndromes with focal femoral deficiency: Strengths and weaknesses of prenatal sonography. *J Ultrasound Med* 2004; 23: 1511–1516.
14. Ackman J, Altiok H, Flanagan A, Peer M, Graf A, Krzak J *et al.*: Long-term follow-up of Van Nes rotationplasty in patients with congenital proximal focal femoral deficiency. *Bone Joint J* 2013; 95-B: 192–198.